

Processed Allogenic Dentine as A Scaffold for Bone Healing: An in vivo study.

¹Dr. AL-Namnam, N.M., ¹Shanmuhasuntharam, P., ¹Dr. Ha K.O. and ²Prof. Siar C.H.

¹Department of Oral & Maxillofacial Surgery and ²Department of Oral Pathology, Oral Medicine & Periodontology, Faculty of Dentistry, University of Malaya, Kuala Lumpur, Malaysia

Abstract: Processed Allogenic Dentine as A Scaffold for Bone Healing: An in vivo study Purpose: (i) to assess the osteo-compatibility of dentine in vivo; (ii) to evaluate the ability of liquid nitrogen treated allogenic dentine to accelerate bone healing compared to normal healing in ungrafted defect, and (iii) to compare quantitatively the amount of new bone formation in the allogenic dentine treated defect to autogenous bone treated defect. **Methods:** Allogenic dentine of New Zealand White rabbits was treated with liquid nitrogen for 2 weeks. In sixteen rabbits, a defect (diameter: 5 mm) was created in each femur for grafting with either allogenic dentine (experimental groups) or autogenous bone (positive control), and in another four rabbits a defect (diameter: 5 mm) was created in each femur and left ungrafted (negative control). The rabbits were sacrificed at 2, 4, 8 and 12-week intervals. **Results:** Histologically, dentine-bone union has been achieved with no signs of inflammation. Histomorphometric, there was no significant difference in bone regeneration between the groups ($p>0.05$). However, the difference was clinically significant between the experimental and negative control groups at 2, 4 and 12 weeks. **Conclusion:** Results suggest that the liquid nitrogen-treated dentine is osteo-compatible and effective as a bone substitute for accelerating bone repair.

Key words: Dentine, Autograft, Allograft, Liquid nitrogen, Bone Substitute.

INTRODUCTION

Many new products of bone graft substitute continue to be developed, surgeons must be sure to understand the mechanism of action of these products and the process by which they treated. As always, patient safety and benefit should be the first considerations.

Bone and dentine are organic-inorganic hybrid composites of protein and mineral with superior strength, hardness and fracture toughness. The capability of dentine matrix to stimulate angiogenesis (Pearce, S.C., 1996), its capacity to be a carrier (Murata, M., 2005), and the presence of BMP in dentine matrix that induce bone and increase it (Gomes, M.F., 2007), all of these properties offer an exciting avenue to choose the dentine as a bone graft substitute for bone regeneration.

Hydroxyapatite [$\text{Ca}_{10}(\text{PO}_4)_6(\text{OH})_2$] is the principal inorganic component of the dentinal matrix. It promotes growth of bone tissue directly on its surface, provides a suitable scaffold for bone deposition and encourages bone regeneration at the surface of the implant. Therefore, it is regarded to be a bioactive material that is ideal for hard tissue regeneration (Cook, S.D., 1992).

It is known that allogenic, demineralized, and lyophilized dentine induced new bone formation without inflammatory or foreign body reactions (Pinholt, E.M., 1990). The biocompatibility of freeze-dried allogenic dentin powder as apical material has been studied, where the tested material is non-irritative and compatible with periapical tissue, and clinically applicable as apical barrier material (Yoshida, T., 1998). Another form of allogenic dentine has been studied for their potential use as bone substitutes. In this study, the dentine showed excellent biocompatibility in vitro, stimulated formation of new bone and was completely incorporated into the new bone in vivo (Moharamzadeh, K., 2008).

For graft processing, a new method of reconstruction utilizing autograft harvested from tumor-bearing area which was subjected to the hypothermic effect of liquid nitrogen, no significant difference in compression strength between intact bone and liquid nitrogen-treated bone was found. However, in autoclaved bone the strength was decreased (Tsuchiya, H., 2005).

Corresponding Author: Dr. AL-Namnam, N.M., Department of Oral & Maxillofacial Surgery, Oral Medicine & Periodontology, Faculty of Dentistry, University of Malaya, Kuala Lumpur, Malaysia
Phone number: +60176258143 Fax number: 03-79674534
E-mail: nis_moh2007@yahoo.com

Dentine has been studied in its pure form and in combination with different materials such as Plaster of Paris, BMP-2 and with PRP and treated with different methods for use as a bone graft substitute. In all these applications, dentine demonstrated its effectiveness in repair and regeneration of bone. However, hence now there is no study that evaluated the efficacy of liquid nitrogen-treated allogenic pure dentine as a potential bone graft substitute. In view of this lack of information the current study was performed to clarify this issue.

MATERIAL AND METHODS

Animals:

Twenty New Zealand White male rabbits (6 months old, 3-3.5 kg) were used in this experiment. Animal selection and management, surgical protocol, and preparation were approved by ethical principles set forth by the Faculty of Medicine, University of Malaya, Kuala Lumpur, Malaysia, and with the approval of the Ethics Committee for Animal Experimentation (Animal Care and Use Committee (ACUC)) number PM/12/08/2008/NMNA (R). The rabbits were randomly assigned into three groups: (1) Experimental group: bone defects filled with allogenic dentine (n=16 defects) (2) Positive control group: bone defect filled with autogenous bone (n= 16 defects) and (3) Negative control group: bone defect not filled (n=8 defects).

Graft Processing:

To prepare the dentine particles for use as allografts, the central incisors were extracted from extra four New Zealand White rabbits. The extracted teeth were washed. Soft and hard deposits were removed. The pulp tissue was totally removed by retrograde technique and anatomical crowns of the teeth were removed with a separating disc to exclude the crown. Only the roots were used, and these were planed to get pure dentine. 70 mg of dentine was placed inside the cryotube and crashed under -169°C in liquid nitrogen (MVE Vapour shippers M02-SC4/3V) as liquid nitrogen protocol (Tsuchiya, H., 2005) for 2 weeks (Zhaohui, F., 1999), thawed it gradually by leaving it at room temperature for 15 min. The dentine was particulated with mortar and pestle into small pieces (2-4 mm) and immersed in a sterile glass container filled with a 0.2 ml gentamycin solution of 70% ethyl alcohol (q.s. 5ml) for 30-60 min to store and disinfect.

Surgical Procedures:

All surgical procedures were performed under systemic (30 mg/kg of ketamine 100 mg/ml (Troy laboratories PTY. Limited, Smithfield, Australia) and 3 mg/kg of xylazine 20 mg/ml (Troy laboratories PTY. Limited, Smithfield, Australia)) and local anesthesia (2% lidocaine with 1:80,000 epinephrine). Skin and superficial fascia incision was made along the cranial border of the shaft of the femur. The superficial leaf of the fascia lata was incised along the cranial border of the biceps femoris muscle. The fascial aponeurotic septum on the lateral shaft was incised. The vastus lateralis and intermedius, and biceps femoris muscles were retracted. Two round bone defect 5 mm in diameter were created in the lower third of the shafts of the femurs one in each femur. The harvested bones were kept in the normal saline. In each of the first 16 rabbits, the defects were randomly grafted with allogenic dentine (experimental) (Fig 1a) in one femur whereas the second femur was grafted by autogenous bone (positive control) (Fig 1b) that was previously harvested. In the last four rabbits the defects were left ungrafted (negative control) (Fig c). The fascia and skin were closed using Vicryl (4-0) sutures and nylon suture (3-0) subsequently.

Post-Operation the animals were supplied according to their weight with an intramuscular injection Kombitrim® 1ml/10kg (sulfamethoxazole and trimethoprim) (Kela Laboratoria n.v, Hoogstraten, Belgium) and meloxicam between 0.3 - 1.5 mg/kg Based from the information from American Association for Laboratory Animal Science's journal (Turner, P.V., 2006) for three days to protect against the Post-Operation infection. The rabbits were sacrificed at 2, 4, 8 and 12 weeks.

Tissue Preparation:

The bone containing the surgical defect was removed en bloc, fixed in 4% paraformaldehyde solution for at least 72 h before they were transferred to a decalcifying agent consisting of 10% Ethylenediaminetetraacetic acid (EDTA) disodium salt solution (ph 6.9) and immersed in this solution for 30 days to decalcify the specimens and embedded in paraffin. Longitudinal Four μm thick sections were obtained by Microtome (Leica, Mannheim, GERMANY). The sections were stained with hematoxylin-eosin.

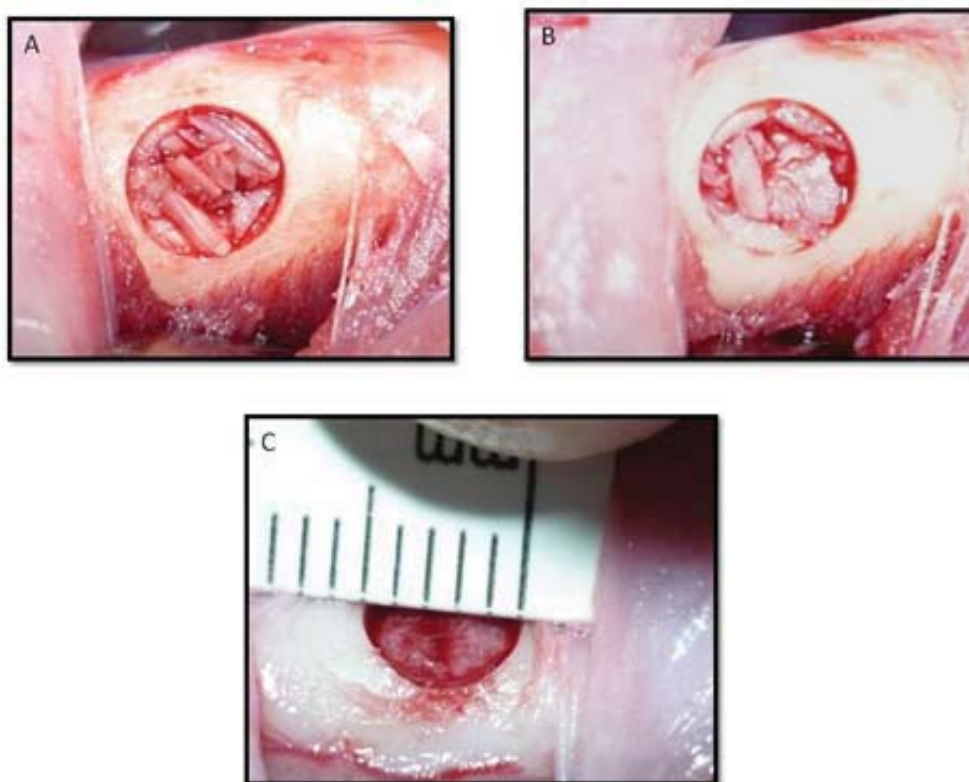


Fig. 1: The defects treated with allogeneous dentine (A) and autogenous bone (B), and the ungrafted defects (C).

Histomorphometric Analysis:

Computer-assisted histomorphometry based on the point-counting technique was performed to quantify the volume density of newly-formed bone in all 3 groups. For each H&E section, 5 microscopic fields were selected: 4 peripheral and one central from the defect site. These histological images at magnification of x 40 were digitally captured using a CCD camera (MicroPublisher 5.0, Q Imaging Inc., Surrey, CANADA) mounted onto the binocular microscope NIKON ECLPSE E400 (Nikon, Inc., Tokyo, JAPAN) and stored in the computer. Quantification was performed using the Image-Pro Express software (Media Cybernetics Inc., Bethesda, MD, USA) for Windows. A grid with 20 points was superimposed on the digitized image for measuring the volume of new bone formation in the defect using the point-counting method. The number of the points that occurred on the newly formed bone matrix was quantified. The values obtained were converted into bone density and expressed as mean percentages using the equation $(BD = N_{bone} / N_{total})$, where the BD is the bone density, N_{bone} is the number of points in bone trabeculae, and N_{total} is the total number of points in the bone defect. The area of new bone formation was expressed as a mean percentage of the total area of the defect. The histomorphometric results were submitted to analysis of variance (SPSS, version 12). Wilcoxon *T*-test and Mann-Whitney *U*-test was used to compare the mean percentage of bone regeneration between the experimental and positive control, and between experimental and negative control groups subsequently at each period of sacrifice. The level of significance was set at $p < 0.05$.

Result:

Histological Observations:

weeks (negative control): Fine trabeculae of immature bone near the defect margin were observed. Abundant connective tissues were distributed on the surface and inside the cavity defect (Fig 2a)

2 weeks (positive control and experimental): The defects were clearly outlined and were filled with a variable quantity of irregular woven bone trabeculae with primitive bone marrow, cellular tissues and grafted

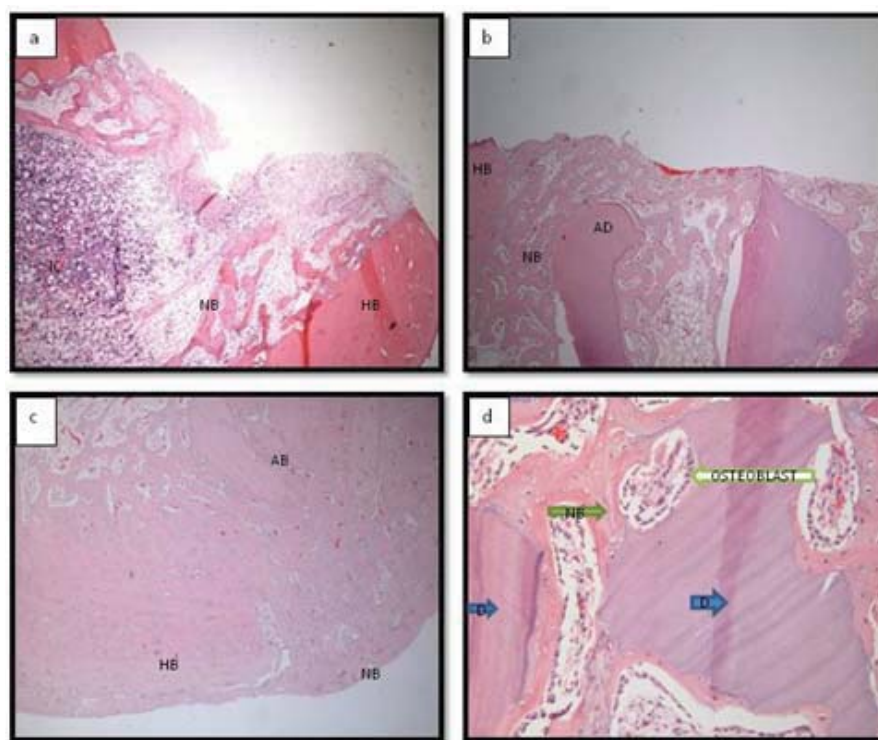


Fig. 2: Photomicrograph of defects sites (2 weeks) showing thin new bone trabeculae (NB) near the defect's margin of the host bone (HB) in (a) negative control, whereas the NB filled and closed the defect treated with allogenous dentine (AD) in (b) and autogenous bone (AB) in (c) (hematoxylin-eosin; x 40). The NB fused to the AD in (d) experimental site (hematoxylin-eosin; x 400).

material (Figs 2b and 2c). Both the experimental and positive control sites showed new bone formation localized in the graft areas as well as at the host bone-graft interface. Large quantities of osteoid tissue were detected adjacent to the grafted dentine and bone particles. the newly formed bone appeared to be distributed along the periphery of the dentine particles and fused to them (Fig 2d) whereas in the bone graft particles it may be found at the periphery, entrapped or fused to the bone graft particles.

4 weeks (negative control): Fine trabeculae of woven bone (immature bone) covered most of the defect surface (Fig 3a). Bone formation commenced along the margin of the defect progressing centrally. Osteon formation near the lateral border of the defect was evident. A few osteoclasts adjacent to the immature bone trabecula were noted.

4 weeks (positive control and experimental): The newly formed bone trabeculae were fused and incorporated into the grafted particles to form bridge which closed the defect surface (Figs 3b and 3c). Mature lamellar bone characterized by large osteon with haversian canals were present (Fig 3d). The bone-grafted particles resorbed more than dentine grafted particles and the margins of pre-existing bone tissue showed areas remodeling.

8 weeks (negative control): The defect was not completely filled by bone. Bone trabeculae were discontinuous in the centre and continuous at the margins (Fig 4a).

8 weeks (positive control and experimental): a large quantity of bone tissue closed positive control and experimental defects' surface that formed by a highly cellularized immature trabeculae and mature bone, with large medullary space (Figs 4b and 4c). Within the bridge, there was quantity of osteogenic connective tissues, which were a highly cellularized. Some of the dentine particles were resorbed. Whereas, the bone graft particles were sub-totally resorbed. There were areas of bone remodeling and apposition. Many osteoclasts housed the lacuna around the grafts particle and newly formed bone. Many osteon has been formed with large haversian canals. The grafted particles that accidentally get inside the bone marrow and the new bones formed around it were much-resorbed.

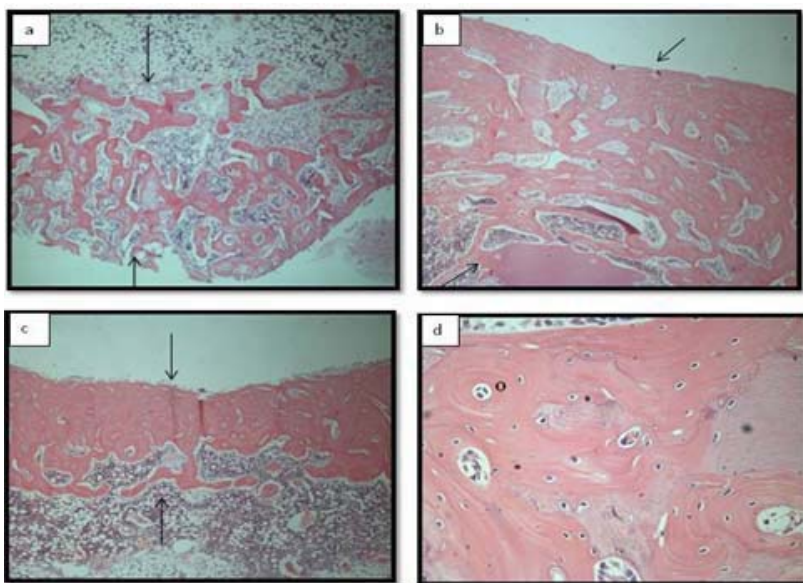


Fig. 3: Photomicrograph of The bone defects region (4 weeks) are filled by scatter and thin immature bone trabeculae and osteogenic connective tissue in (a) negative control. Whereas, they closed with thick woven bone (WB) in (b) experimental and (c) positive control sites (hematoxyline-eosin; x 40) that began to mature and form large osteon haversain canals (O) in (c) experimental site (hematoxyline-eosin; x 400).

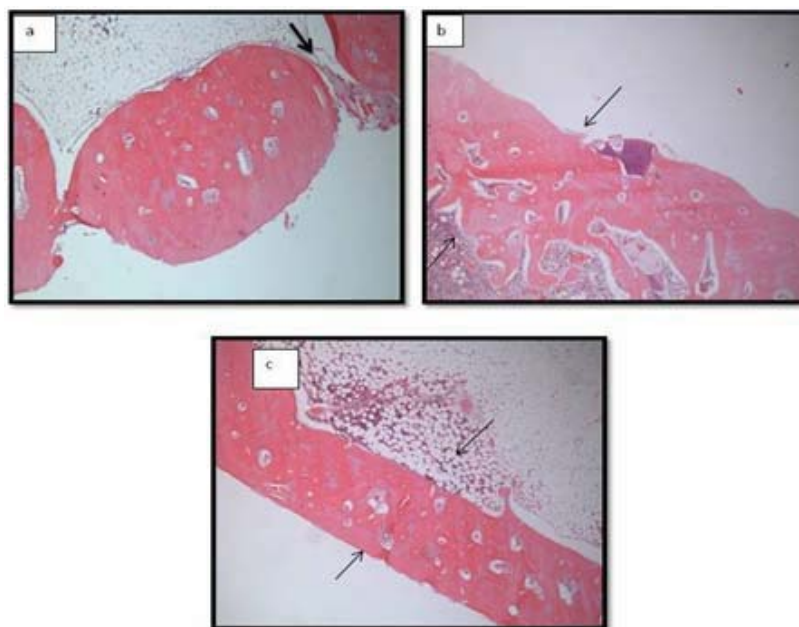


Fig. 4: Photomicrograph of defects sites (8 weeks) showing non-continuous bone tissue layers in (a) negative control. Large quantity of bone tissue closed their surface that formed by a highly celularized and more mature bone in (b) experimental and (c) positive control sites (hematoxyline-eosin; x 40).

12 weeks (negative control): In the negative control, the defect was not completely filled by bone trabeculae. It showed a discontinuous bone tissue layers centrally whereas it was continuous at the margins, and this covered the superficial portions of the defects. Numerous osteoclasts in Howship's lacunae were observed at this stage more than those at 8 weeks. Osteogenic connective tissue filled the central gap of the defect (Fig 5a).

12 weeks (positive control and experimental): The newly formed bone closed the defect completely (Figs 5b and 5c). The newly formed bone made as a bridge that arranged in lamellar form in some areas with large osteon and haversian canals with a highly cellularized connective tissues within it at the central part. The connective tissues within the bone bridge in positive control less than that in the experimental defects. The bridge is thicker in positive control defects than that in experimental defects. No bone grafts particles were seen in 12 weeks, whereas there were few very small dentine particles.

Histomorphometric Analysis:

Mean percentage of newly formed bone in the experiment was comparable to the positive control and greater than that of the negative control groups in all observation time (Table 1 and fig. 5). There was no significant difference in bone regeneration between the groups ($p>0.05$). However, the difference was clinically significant between the experimental and negative control groups at 2, 4 and 12 weeks.

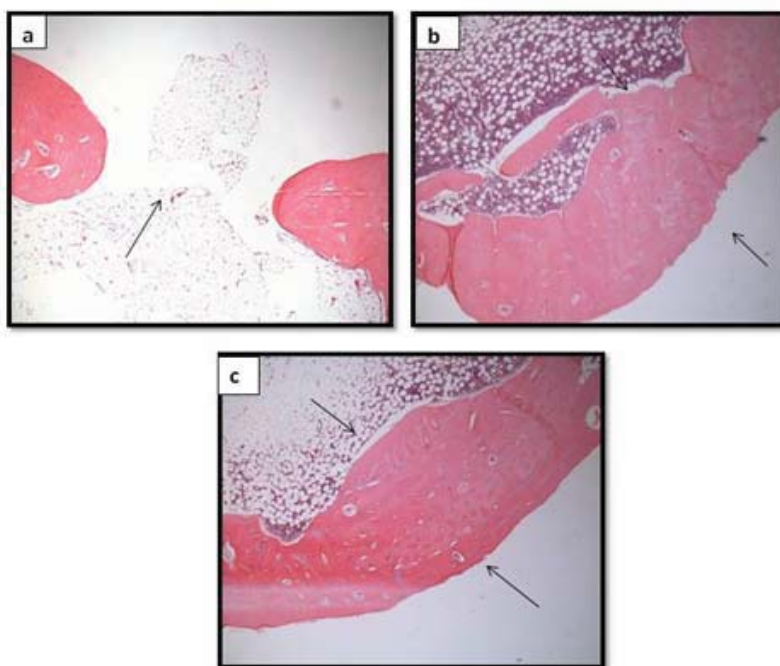


Fig. 5: Photomicrograph of defects sites (8 weeks) showing formed bone was not completely filled by bone trabeculae in (a) negative control. Whereas, it was closed the defect completely in (b) experimental and (c) positive control sites (hematoxyline-eosin; x 40).

Table 1: New bone formation (Mean \pm SD) at sacrifice time in all groups.

Time of sacrifice	Negative control	Experimental	Positive control
2 weeks	5.7 \pm 1.4	24.8 \pm 8.1	26.5 \pm 8.9
4 weeks	18.8 \pm 3.0	32.5 \pm 8.0	34.3 \pm 7.0
8 weeks	29.7 \pm 4.2	31.9 \pm 6.8	32.6 \pm 6.7
12 weeks	26.0 \pm 3.8	34.5 \pm 4.6	38.2 \pm 4.8

Discussion:

Researchers demonstrated the biocompatibility of freeze-dried dentine in the periapical tissues when used as an apical barrier material (Yoshida, T., 1998; Rossmeisl, R., 1982). Rapid freezing and slow thawing are

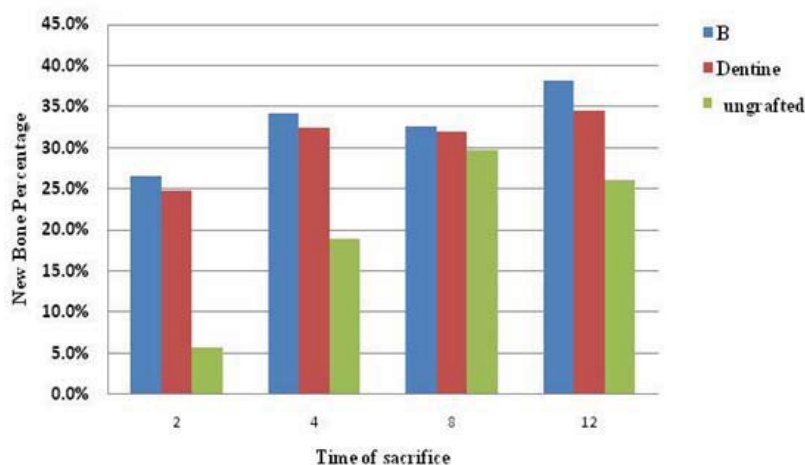


Fig. 6: Bone generation in all groups at the time of sacrifice.

most lethal to mammalian cell and cause low recovery of cells after cryopreservation. The antigenicity of human homograft aortic valve decreased to the lowest level by treating it in the liquid nitrogen for 2 weeks (Zhaohui, F., 1999). In the present work, we immersed the root dentine in the liquid nitrogen at -196°C in order to destroy all the vital cells and denaturized the protein that can evoke an immune reaction as the Rapid freezing and slow thawing are most lethal to mammalian cell and cause low recovery of cells after cryopreservation. Our results showed that the liquid nitrogen-treated allogenic dentine was osteocompatible.

Osteoconduction is the process by which implanted inorganic material provides matrix permitting bone-producing cells to grow from the defect margin. In the present study as the dentine consists of both organic and inorganic material, the latter mainly hydroxyapatite, the bone producing cells grow all around the particles from the defect margin centripetally to form an osseous bridge to close the defect completely. This observation provides histological evidence supporting the osteoconductivity properties of dentine.

Many materials used for their osteoconductivity include materials such as alloplast and xenograft. The advantage of dentine over these other grafts in addition to its neutrality that has nearly the same properties of the bone, is its structure which consists mainly of hydroxyapatite. HA is present in the other material, is inexpensive comparable to other substance such as the calcium phosphate which is more costly.

The advantage of bone regeneration with the autologous bone or biomaterials was faster and complete ossification as minimizing the risk of fracture and implants osseointegration (Bodner, L., 2000; Chiapasco, M., 2000). In the present work at 2 and 4 weeks the rate of the bone regeneration was higher and clinically significant in the experimental site than that in the negative control site and this means that greater strength is achieved thereby decreasing the possibility of femur fracture at the surgical defect site.

The complex molecular interaction occurring between bone and dentine matrices might influence the speed, lifespan of osteoblastic and osteoclastic cells (Carvalho, V.A., 2004; Mundy, G.R., 1982). In the present work, the rate of new bone formation in the positive control and experimental sites increased exponentially with time. However, at 8 weeks this rate started to decline and this was due to the presence of abundant osteoclasts at this stage. Nevertheless, the rate of bone healing continued to increase again at 12 weeks. In the negative control site, this bone-healing rate increased continuously at 2, 4 and 8 weeks and decreased at 12 weeks. The present author hypothesized that the intense process of bone remodeling that occurred in dentine and bone particle grafted sites and the amount of the newly formed bone at 8 weeks helped explains this phenomenon since bone remodeling consists essentially of two processes that is resorption and deposition of bone matrix. These results were in agreement with the findings of Carvalho (Carvalho, V.A., 2004). Furthermore, the presence of the graft as necrotic tissue acts as a chemotactic factor for osteoclastic migration. Furthermore, osteoclastogenesis is mediated via ligation of RANKL to its transmembranal receptor, RANK. Enhanced osteoclastogenesis is associated with high expression of otherwise TNF and RANKL-induced mediators. This phenomenon explained that the remodeling process was initiated earlier in the positive and experimental sites (8 weeks) than in the negative control (12 weeks). Thus, bone remodeling and deposition are accelerated during the initial period following graft placement and these observations were in agreement with Gosain and his associate (Gosain, A.K., 1999).

The use of bone substitute materials that possess properties similar to those of autogenous bone graft is advantageous as it may help the healing rate in the bone defect, accelerate or guide the repair of the bone defect. In the present study, the defect was healed completely at 12 weeks in the allogenic dentine-treated and autogenous bone-treated defects, but not in the negative control. This is evidence of the ability of the dentine to accelerate bone healing. These findings were in accordance with the findings in Andersson study (Andersson, L., 2009).

In the present study, the surgical defects created were 5mm in diameter because of the width of the femur, which is 7mm, we could not increase the size of the defect otherwise it will break. Therefore, we added the negative control group (normal healing) to see how the dentine will aid in the healing of the defect. The result showed that the new bone trabeculae were formed in all the defects at 2 and 4 weeks. However the rate of bone healing was higher in the experimental than in the negative control. The results suggest that dentine could play a supportive role in the early repair process and provides a favourable surface for osteoprogenitor cell attachment.

The difference between the experimental and negative control was clinically significant but not statistically significant because of simple size of the negative control group was small that could not show the difference statistically.

The dentine particles were nearly disappeared during the bone healing in our experimental period (12 weeks). This phenomenon is attributed to the resorption replacement of the graft particle.

The autogenous bone graft remains the ideal material for transplantation because it lacks the immunogenicity, aid in osteogenesis, is osteoinductive and provides structure support through the healing process (Jay, R.M., 1999). In agreement with Cavalcanti (Cavalcanti, S.C., 2008) and in contrast with previous studies, we used the autogenous bone as a positive control in this study to confirm the efficacy of dentine as a bone regenerative substitute and to confirm its superiority. However, our results showed that both showed adequate rate of bone healing with no significant differences.

In the daily dental practice, extracted teeth are unfortunately usually discarded. Extracted teeth from healthy patients could be prepared, stored for use as a bone substitute as it is less time consuming, cost-saving, clinically manageable and easily preserved. These allogenic dentine can be used as a bone graft substitute for different clinical situations including guided bone regeneration in endosseous implant, elevation of sinus floor and alveolar ridge, filling of defects left following removal of tumors.

The good osteocompatibility without eliciting inflammatory reaction or infiltration of body giant cells, the osteoconductivity and the ability to be replaced by new bone indicates that the allogenic liquid nitrogen-treated dentine has the potential to be used as an osteoconductive bone substitute which provides a physical matrix for new bone deposition.

Conclusion:

Allogenic dentine was comparable to autogenous bone in two main respects; it is osteocompatible and has the potential to be an osteoconductive bone substitute, which provides a physical matrix for the new bone deposition. It is effective as a bone substitute for accelerating bone repair.

ACKNOWLEDGMENTS

The research was funded by the University of Malaya Postgraduate Grant (PS032/2008B and PS075/2009A). We gratefully acknowledged the support and encouragement of the following: Dean, Faculty of Dentistry, Head, Department of Oral & Maxillofacial Surgery and technical staff, Animal House and Oral Pathology Diagnostic Laboratory.

REFERENCES

- Andersson, L., A. Ramzi, B. Joseph, 2009. Studies on dentine grafts to bone defects in rabbit tibia and mandible; development of an experimental model. *Dental Traumatology*, 25: 78–83.
- Bodner, L., 2000. Spontaneous bone regeneration after enucleation of large mandibular cysts: a radiographic computed analysis of 27 consecutive cases. *Journal of Oral and Maxillofacial Surgery*, 58: 949.
- Chiapasco, M., A. Rossi, J. Motta, M. Crescentini, 2000. Spontaneous bone regeneration after enucleation of large mandibular cysts: A radiographic computed analysis of 27 consecutive cases. *Journal of Oral and Maxillofacial Surgery*, 58: 942-8.

Carvalho, V.A., O. Tosello Dde, M.A. Salgado, M.F. Gomes, 2004. Histomorphometric analysis of homogenous demineralized dentine matrix as osteopromotive material in rabbit mandibles. *International Journal of Oral & Maxillofacial Implant*, 19: 679- 86.

Cook, S.D., T. Albrektsson, R.A. Yukna, G. de Lange, 1992. "Current issues forum: What is your opinion concerning the long-term consequences of HA coatings within bone,.". *International Journal of Oral & Maxillofacial Implant*, 7: 302-10.

Cavalcanti, S.C., C.L. Pereira, R. Mazzone, M. de Moraes, R.W. Moreira, 2008. Histological and histomorphometric analysis of calcium phosphate cement in rabbit calvaria. *Journal of Cranio-Maxillofacial Surgery*, 36: 354-9.

Gomes, M.F., E.C. Banzi, M.F. Destro, V. Lavinicki, M.G. Goulart, 2007. Homogenous demineralized dentin matrix for application in cranioplasty of rabbits with alloxan-induced diabetes: histomorphometric analysis. *International Journal of Oral & Maxillofacial Implant*, 22: 939-47.

Gosain, A.K., L. Song, T.D. Santoro, M.T. Amarante, D.J. Simmons, 1999. Long-term remodeling of vascularized and nonvascularized onlay bone grafts: a macroscopic and microscopic analysis. *Plastic and Reconstructive Surgery*, 103: 443-50.

Jay, R.M., 1999. *Pediatric foot & ankle surgery*, Elsevier Health Sciences.

Murata, M., 2005. Bone engineering human demineralized dentin matrix and recombinant human BMP-2. *Journal of Hard Tissue Biology*, 41: 80-1.

Moharamzadeh, K., C. Freeman, K. Blackwood, 2008. Processed bovine dentine as a bone substitute. *British Journal of Oral and Maxillofacial Surgery*, 46: 110-3.

Mundy, G.R., S.B. Rodan, R.J. Majeska, S. DeMartino, C. Trimmier, T.J. Martin, G.A. Rodan, 1982. Unidirectional migration of osteosarcoma cells with osteoblast characteristics in response to products of bone resorption. *Calcified Tissue International*, 34: 542-6.

Pearce, S.C., O. Hudlicka, A.J. Smith, 1996. In vivo effects of dentine matrix on angiogenesis in rat skeletal muscle. *Journal of Dental Research*, 75: 1173.

Pinholt, E.M., G. Bang, H.R. Haanaes, 1990. Alveolar ridge augmentation by osteoinduction in rats. *Scand J Dent Res*. 98: 434-41.

Rossmesl, R., A. Reader, R. Melfi, J. Marquard, 1982. A study of freeze-dried (lyophilized) dentin used as an apical barrier in adult monkey teeth. *Oral Surgery, Oral Medicine, Oral Pathology, Oral Radiology, and Endodontology*, 53: 303-10.

Tsuchiya, H., S.L. Wan, K. Sakayama, N. Yamamoto, H. Nishida, K. Tomita, 2005. Reconstruction using an autograft containing tumour treated by liquid nitrogen, *Journal of Bone and Joint Surgery*, 87: 218-25.

Turner, P.V., H.C. Chen, W.M. Taylor, 2006. Pharmacokinetic of meloxicam in rabbits after single and repeat oral dosing, *Comparative Medicine*, 56: 63-67.

Yoshida, T., T. Itoh, T. Saitoh, I. Sekine, 1998. Histopathological study of the use of freeze-dried allogenic dentin powder and True Bone Ceramic as apical barrier materials. *J Endod*. 24: 581-6.

Zhaohui, F., H. Qingheng, Z. Jian, 1999. Experimental study of influence of liquid nitrogen preservation on antigenicity of human homograft aortic valve. *J Xi'an Medical University*, 11: 157-61.